

## CASE REPORT

# Utilizing fractional resurfacing in the treatment of therapy-resistant melasma

ZEINA S. TANNOUS<sup>1,2</sup> & SUSANNE ASTNER<sup>1</sup>

<sup>1</sup>Department of Dermatology, Massachusetts General Hospital, Harvard Medical School, Boston, Massachusetts, USA, and

<sup>2</sup>Wellman Center of Photomedicine, Massachusetts General Hospital, Harvard Medical School, Boston, Massachusetts, USA

### Abstract

**Background.** Multiple treatment modalities have been employed for the management of melasma with minimal to no success.

**Objective.** We propose fractional resurfacing as a new treatment modality for melasma.

**Methods.** A 31-year-old Caucasian female with facial epidermal and dermal melasma, resistant to multiple courses of topical therapies, was treated with two sessions of full-face fractional resurfacing (Fraxel<sup>TM</sup> Laser; Reliant technologies, San Diego, CA), separated by a three-week interval. Clinical improvement was assessed by Wood's Lamp examination as well as parallel and cross-polarized comparative photography at baseline and 6 months later.

**Results.** Marked reduction in epidermal and dermal facial pigmentation was observed at the six-month follow-up visit.

**Conclusion.** Fractional resurfacing may prove to be an effective and safe treatment modality for lightening of the epidermal and dermal pigmentation of melasma. Further studies with long-term follow-up periods and multiple patients with diverse skin phototypes and different variants of melasma are warranted

**Key words:** Laser treatment, melasma

### Introduction

Melasma, also known as chloasma and the 'mask of pregnancy', is an acquired brown macular hyperpigmentation, usually of the face. It is nine times more common in females than males. Melasma usually presents bilaterally and symmetrically on the face, but extensor forearms may also be involved. Sun exposure, pregnancy and oral contraceptive pills have all been associated with its presentation.

There are three types of melasma including: epidermal, dermal and mixed variants.

The pathogenesis of this common skin disorder remains unknown, and various therapeutic modalities have been employed with minimal to no success (1).

Fractional resurfacing (FR) is a new concept of skin rejuvenation that produces a unique thermal damage pattern (2). FR produces multiple columns of thermal damage, referred to as microthermal treatment zones (MTZ), and characteristically spares the tissue surrounding each column. The histology of a microthermal treatment zone (MTZ) shows homogenization of dermal matrix and the

formation of microscopic epidermal necrotic debris (MEND) (2). MENDs are thought to represent the elimination of the damaged epidermis containing the pigment in the basal cell layer facilitated by the movement of the rapidly migrating viable keratinocytes present at the wound margins. This process might explain why FR might provide a promising modality in the treatment of melasma. We present a patient with therapy-resistant melasma treated with two sessions of FR and her follow-up at 6 months.

### Case presentation

We present a 31-year-old Caucasian female, Fitzpatrick skin phototype II–III, with centrofacial and malar melasma that was treated successfully with fractional resurfacing.

Patient's past medical history was significant for moderate sun exposure with multiple blistering sunburns. She was never pregnant. At age 22, she began a one-year course of oral contraceptives. Her melasma initially presented at 23 years of age and persisted, with minimal fading during winter

months. Prior to treatment with FR, the patient had been treated with multiple courses of topical therapies, including 4% hydroquinone cream, tretinoin cream, as well as Triluma<sup>®</sup> cream (fluocinolone acetonide 0.01%, hydroquinone 4%, tretinoin 0.05%), in combination with strict sun protection and daily application of SPF 30 sunscreen, with only mild to no improvement.

Physical examination revealed a light to dark brown symmetric macular hyperpigmentation in a centrofacial and malar distribution (Figure 1a–c, Figure 2a–c). Wood's light examination revealed partial accentuation of the epidermal pigmentary component. Other areas revealed a brown-gray color suggestive of mixed epidermal and dermal melasma. There was no history suggestive of post-inflammatory hyperpigmentation, exogenous ochronosis or drug-induced hyperpigmentation.

The patient underwent two treatments with the fractional resurfacing laser (Fraxel<sup>™</sup> Laser; Reliant technologies, San Diego, CA) to her full face, separated by a three-week period (September and October 2004).

Prior to each treatment, the face was cleansed with soap and water, scrubbed with aluminum chloride crystals and wiped with alcohol. The skin was allowed to dry and FD&C1 water-soluble blue tint was painted on the treatment areas. One hour before the procedure for local anesthesia, 30% topical lidocaine ointment was applied. Treatment was performed at energy settings between 6 mJ and 8 mJ, and a density setting of 250 MTZs/cm<sup>2</sup>. Eight passes were delivered with appropriate overlap to a total density of 2000 MTZ/cm<sup>2</sup>. After each procedure, the face was cleansed, and mild to moderate erythema, resembling a sunburn reaction, was observed. The erythema resolved in 2 days and was easily covered with makeup. It was then replaced with mild bronzing that lasted 2–3 days. The patient experienced no significant swelling. She reported marked improvement in her melasma one week after each treatment. She was seen in follow-up 6 months after her first treatment where she demonstrated marked resolution of her melasma (Figure 1d–f, cross-polarized images; Figure 2d–f, parallel-polarized images).

## Discussion

Melasma is an acquired brown macular hyperpigmentation of the face that is cosmetically displeasing to many patients. Melasma treatment can be frustrating and often ineffective. Dermal and mixed-type melasma are least responsive to therapy. For all melasma patients, sunscreen and sun avoidance are essential components of therapy. There are multiple topical and laser therapies that can be employed for treatment. Topical treatments

include bleaching agents such as hydroquinone, topical tretinoin, and azelaic acid. A combination therapy of fluocinolone acetonide 0.01%, hydroquinone 4%, tretinoin 0.05% (Tri-Luma Cream) (3), can produce favorable clinical results with decreased irritation. Chemical peels, including Jessner's solution, glycolic acid peels as well as trichloroacetic acid peels, can also be used with variable clinical results (4,5).

Laser treatment for melasma is not usually recommended given its high incidence of post-inflammatory hyperpigmentation and its modest efficacy (6,7). Q-switched ruby and Q-switched Nd:YAG lasers are both slightly to moderately effective in treating melasma; however, they both have a high incidence of pigmentary alterations after treatment. In cases refractory to topical creams and chemical peels, Erbium:YAG (8) and carbon dioxide lasers can produce significant improvement in the melasma but are often complicated with post-inflammatory hyperpigmentation. There is a need for less invasive and effective modalities with lower incidence of side effects.

We present, to our knowledge, the first reported case of therapy-resistant melasma treated successfully with FR. The patient has suffered from centrofacial and malar melasma for 9 years, which was resistant to long-term use of multiple courses of topical medications including hydroquinone and tretinoin, coupled with extensive sun protection. She received two sessions of FR treatments in a 3-week interval. The patient demonstrated remarkable and persistent resolution of her melasma at her 6 months follow-up examination (Figures 1 and 2).

FR is a novel concept of skin rejuvenation that has the potential to treat a variety of epidermal and dermal conditions. It produces a unique thermal damage pattern. In contrast to ablative skin resurfacing and nonablative skin resurfacing, which achieve homogenous thermal damage at particular depth, FR creates microscopic thermal wounds, referred to as MTZs (2). FR specifically spares tissue surrounding each MTZ, thus allowing rapid re-epithelialization and fast epidermal repair due to the small size of the wounds and short migratory paths for keratinocytes. Examination of the histology of MTZs shows homogenization of dermal collagen and the formation of MENDs containing melanin (2). MENDs result from the elimination of the damaged keratinocytes with their pigment content, facilitated by the movement of the rapidly migrating viable keratinocytes present at the wound margins. This hypothesis might provide a partial explanation to why FR might prove helpful in the treatment of epidermal melasma. As to the dermal component of melasma, FR might induce disruption of the dermal macrophages containing melanin, releasing melanin granules into the dermis and changing their optical properties.

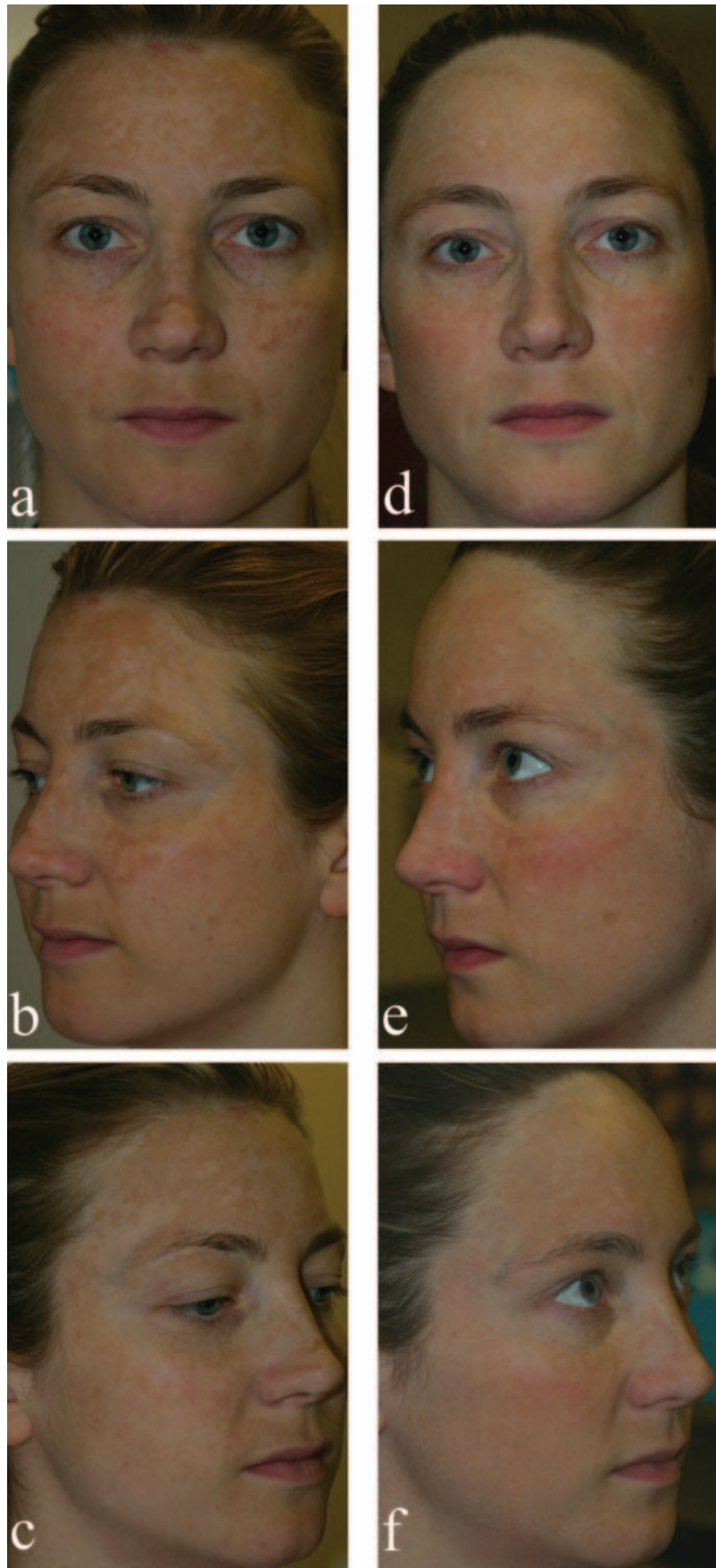


Figure 1. Clinical photographs taken with a cross-polarized digital imaging system. Left panel taken at baseline; 1(a) frontal image, 1(b) left face image and 1(c) right face image. Right panel taken 6 months later; 1(d) frontal image, 1(e) left face image 1(f) right face image. Note the marked resolution of the mixed variant melasma, detected more readily with cross-polarized light.

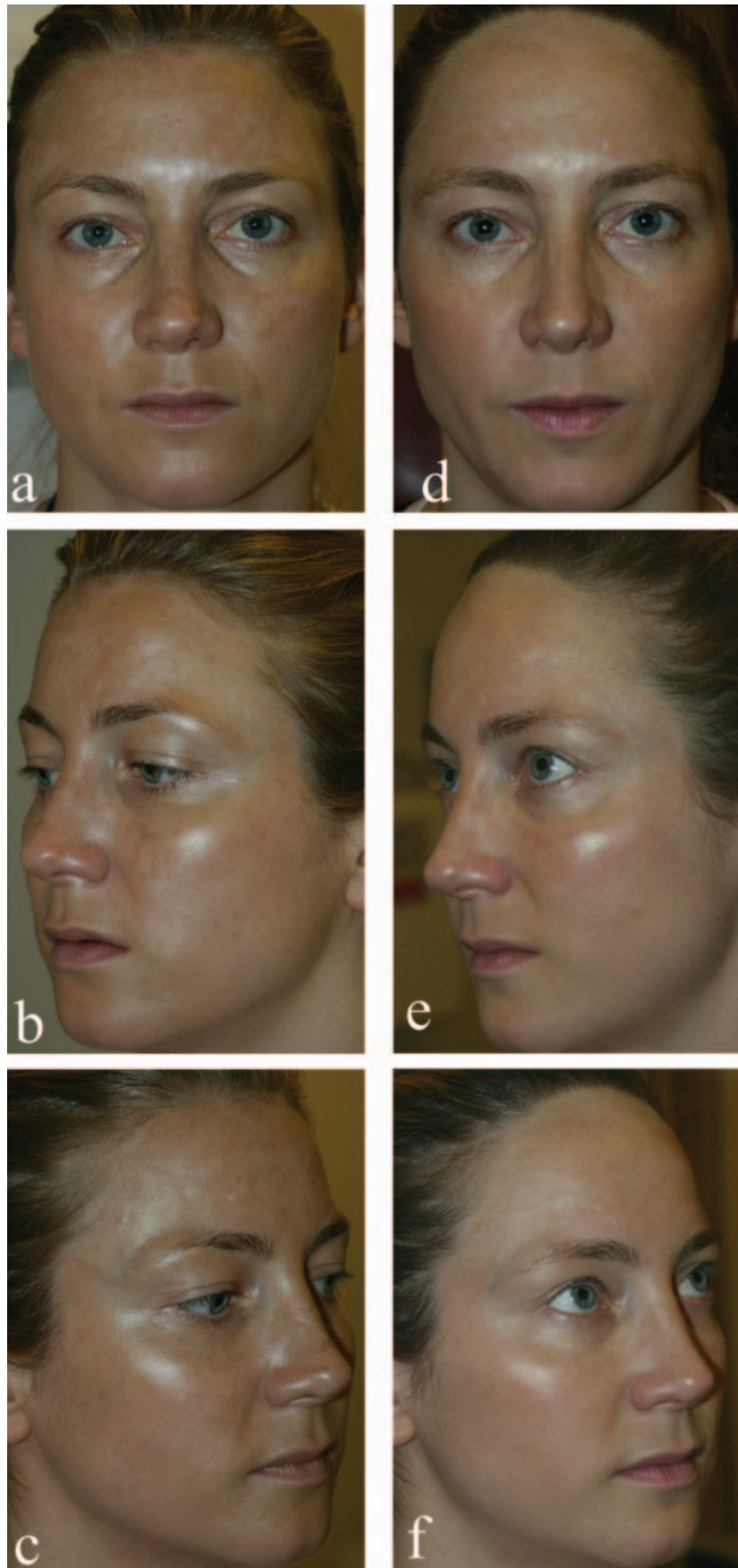

Figure 2. Clinical photographs taken with a parallel-polarized digital imaging system. Left panel taken at baseline; 2(a) frontal image, 2(b) left face image and 2(c) right face image. Right panel taken 6 months later; 2(d) frontal image, 2(e) left face image 2(f) right face image. Note the marked resolution of the mixed variant melasma.

This might be manifested clinically as lightening of the dermal component of melasma.

### Conclusion

We present a case of a young female with recalcitrant melasma treated successfully with fractional resurfacing. We believe that this is a novel, effective and safe treatment for the removal of epidermal and dermal pigmentation associated with therapy-resistant melasma. Long-term follow-up and histological studies are needed to corroborate our findings. Based upon our findings, further studies with multiple patients, diverse skin phototypes, and different variants of melasma are warranted.

### References

1. Victor FC, Gelber J, Rao B. Melasma: a review. *J Cutan Med Surg.* 2004;8(2):97–102.
2. Manstein D, Herron GS, Sink RK, Tanner H, Anderson RR. Fractional photothermolysis: a new concept for cutaneous remodeling using microscopic patterns of thermal injury. *Lasers Surg Med.* 2004;34(5):426–38.
3. Torok HM, Jones T, Rich P, Smith S, Tschen E. Hydroquinone 4%, tretinoin 0.05%, fluocinolone acetonide 0.01%: a safe and efficacious 12-month treatment for melasma. *Cutis.* 2005;75(1):57–62.
4. Hurley ME, Guevara IL, Gonzales RM, Pandya AG. Efficacy of glycolic acid peels in the treatment of melasma. *Arch Dermatol.* 2002;138(12):1578–82.
5. Lee GY, Kim HJ, Whang KK. The effect of combination treatment of the recalcitrant pigmentary disorders with pigmented laser and chemical peeling. *Dermatol Surg.* 2002;28(12):1120–3; discussion 1123.
6. Taylor CR, Anderson RR. Ineffective treatment of refractory melasma and postinflammatory hyperpigmentation by Q-switched ruby laser. *J Dermatol Surg Oncol.* 1994;20(9):592–7.
7. Nouri K, Bowes L, Chartier T, Romagosa R, Spencer J. Combination treatment of melasma with pulsed CO<sub>2</sub> laser followed by Q-switched alexandrite laser: a pilot study. *Dermatol Surg.* 1999;25(6):494–7.
8. Manaloto RM, Alster T. Erbium:YAG laser resurfacing for refractory melasma. *Dermatol Surg.* 1999;25(2):121–3.